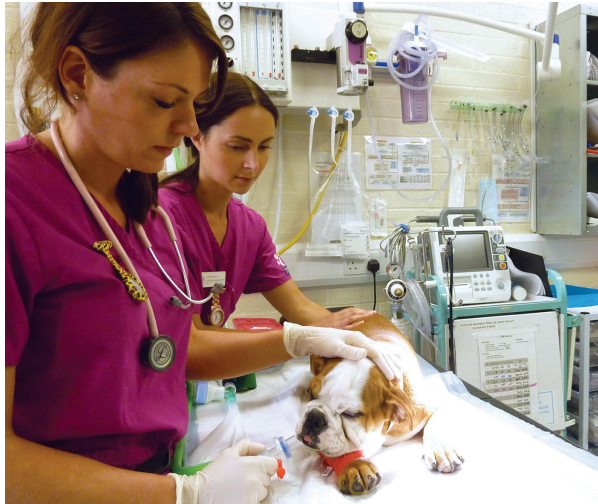

## Aftercare and outcome

Pets are monitored very closely in intensive care immediately after surgery and overnight thereafter. Significant inflammation or bleeding can obstruct the airway, making breathing difficult or impossible. Occasionally (around 5% of cases) a temporary tube must be placed and maintained through an incision in the neck into the trachea (tracheostomy) until the swelling in the throat subsides enough that the pet can breathe normally.



The intensive care unit (ICU) at Dick White Referrals

Dogs which have ongoing respiratory problems despite the treatments listed overleaf may also be recommended to undergo computed tomography (CT, a high definition 3D x-ray) of the head and/or endoscopy of the nasal cavity to assess for additional bone folds within the nose which add to airflow obstruction. If found these may be amenable to removal with a surgical laser.

In cases with severe laryngeal collapse it is sometimes recommended to perform a 'tie back' procedure on the larynx to help open the vocal cords. Another alternative might be to remove part of the larynx to create a wider opening.

The creation of a new permanent opening into the trachea in the neck area (permanent tracheostomy) may be the only solution for cases with advanced stages of laryngeal collapse, although there are complications associated with this procedure.

The prognosis is good for young animals that are only moderately affected at the time of diagnosis. They generally will breathe much more easily and are more tolerant of exercise after resolution of the post operative swelling a few weeks following surgery. Regurgitation episodes are also usually greatly reduced in the longer term following surgery; however, they can be aggravated immediately following anaesthesia and surgery. The prognosis is less favourable for cases with advanced stage laryngeal collapse.

## How to arrange a referral appointment

Following discussion with your own veterinary surgeon, you may request to be referred to Dick White Referrals to benefit from our team of Specialist Soft Tissue Surgeons, who have a wealth of experience in treating dogs affected by BOAS. They also work closely with Specialist colleagues in Anaesthesia and Diagnostic Imaging to ensure the highest possible standards of diagnosis and treatment.

## Getting to Dick White Referrals safely

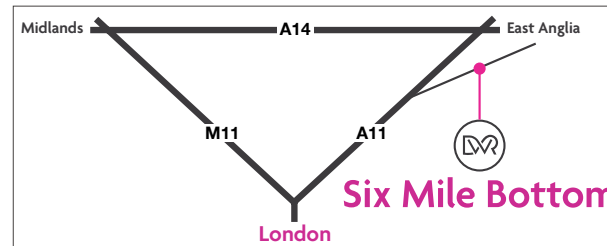
Keep your dog cool and calm during transport.

Mild sedation may be necessary before transportation if felt appropriate by your vet, with whom we are happy to discuss sedative drug use.

Try to avoid transport in the heat of the day in summer. Air conditioning or open windows should be used to keep patients adequately cool, reducing their need to pant.

## What to expect following your consultation

Following consultation with one of our Specialist Soft Tissue Surgeons or a Resident (Specialist Trainee) under their supervision, your dog is likely to be admitted for further assessment and surgery if indicated. This is usually planned within 24 hours of the appointment to minimise patient stress and trips to and from the hospital. Where possible all procedures are performed under a single anaesthetic period to minimise the associated risks.



Dick White Referrals • Station Farm • London Road  
Six Mile Bottom • Cambridgeshire CB8 0UH  
E [softtissuesurgery@dwr.co.uk](mailto:softtissuesurgery@dwr.co.uk)  
T +44 (0)1638 572012 • F +44 (0)1638 572013

[www.dickwhitereferrals.com](http://www.dickwhitereferrals.com)



# Brachycephalic Obstructive Airway Syndrome (BOAS)



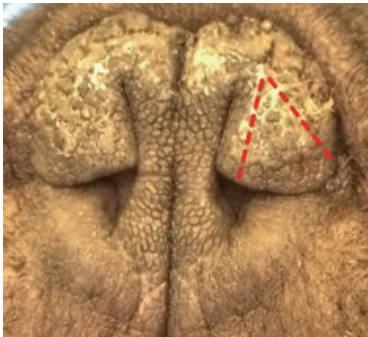
Dick White Referrals  
Excellence. Trust. Care.

## What is BOAS?

The term Brachycephalic Obstructive Airway Syndrome (BOAS) refers to the combination of an overlong soft palate and stenotic nares (narrow nostrils), which are commonly seen in brachycephalic (short-nosed) breeds. These anatomic abnormalities can subsequently lead to secondary problems.

## How do these changes cause problems?

Narrowed nostrils greatly reduce airflow through the nose. An overlong soft palate protrudes into the airway and blocks airflow through the larynx (voice box). Struggling to breathe often leads to swelling and further thickening of the palate. Additionally, some dogs with BOAS are also born with a narrow trachea (windpipe).



**Stenotic nares – red dotted line shows planned surgical incisions to widen the nostril.**

Negative pressure (suction) created by the anatomic malformations described above can frequently lead to progressive stages of laryngeal collapse. Commonly the laryngeal saccules (tissue pockets just in front of the vocal cords) turn inside out, further obstructing airflow. This may also progress to weakening and inward collapse of the vocal cords, increasing the degree of airway obstruction.

Tonsil enlargement occurs due to airway inflammation causing activation of the immune system as well as the result of suction on these delicate structures.

Regurgitation is also common in affected dogs due to negative airway pressures promoting stomach acid reflux as well as a common association with hiatal hernia (weakness of the diaphragm and valve which prevents stomach content reflux).

## Symptoms

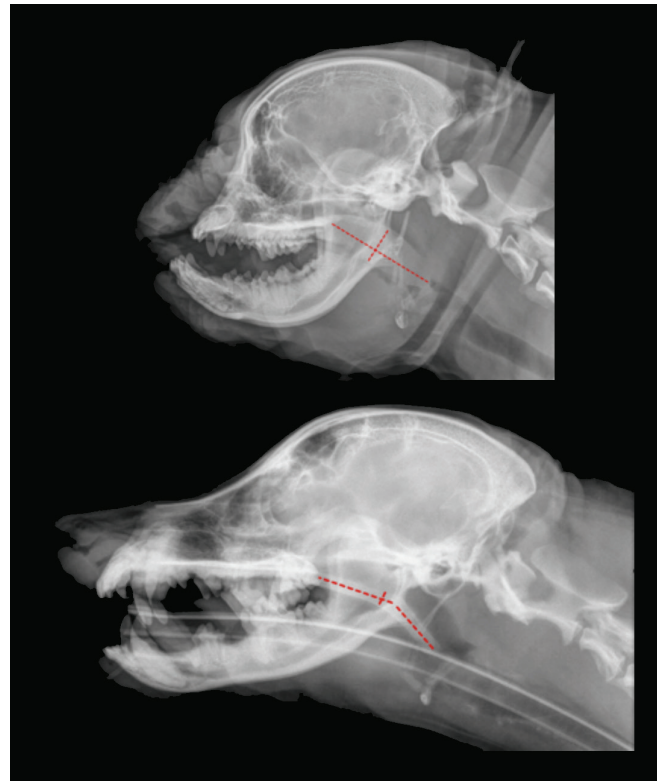Dogs with elongated soft palates generally have a history of noisy breathing and snoring, especially upon inspiration (breathing inward). Some dogs will retch, gag or reverse sneeze due to choking on their overlong palate. Exercise intolerance, cyanosis (blue tongue and gums from lack of oxygen) and occasional collapse are common, especially following over-activity, excitement or excessive heat/humidity. Obesity accentuates the problem by causing further airway narrowing. Many dogs will also regurgitate food, white froth or bile on a regular basis. In some dogs this is the primary problem noted.

## Diagnostics

Stenotic nares are easily observed on physical examination. Also at this time body condition score (BCS) will be assessed on a scale of 1-9, (5 = normal, 1 = very underweight, 9 = obese). Mild or moderately affected dogs may undergo a 3-minute exercise test at a moderate trot to assess changes in their breathing.

Definitive diagnosis of elongated soft palate, tonsil enlargement and laryngeal collapse can only be made under very carefully monitored anaesthesia, using a laryngoscope.

Chest x-rays are taken to evaluate the trachea, lower airways and lungs for evidence of concurrent problems, especially aspiration pneumonia, which may result from inhaling regurgitated stomach contents. It is common to also note multiple spinal abnormalities on x-rays of brachycephalic breeds (although these do not cause a clinical problem in the majority of dogs).



**X-rays to highlight the difference in skull shape and soft palate length and thickness (marked in red) between a brachycephalic dog and one with a longer nose.**

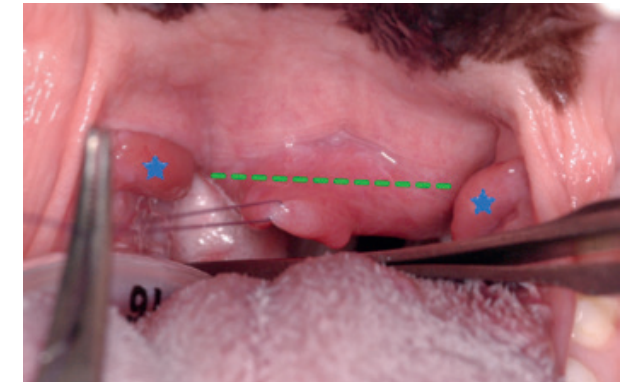
Additionally, dogs presenting primarily with regurgitation may undergo endoscopy of the stomach and small intestine and have biopsies taken to help exclude other causes of intestinal disease, which may be contributing to the problem.

## Treatment

In overweight patients with mild clinical signs, dietary changes alone may be advised.

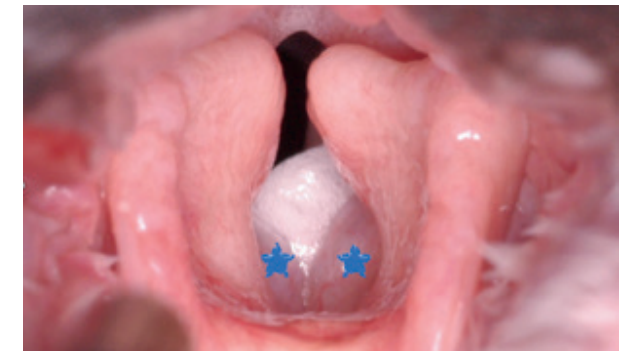Surgical widening of stenotic nares, by removing part of the nose folds, will help to improve nasal airflow.

Soft palate shortening (staphylectomy) or shortening combined with thinning (palatoplasty) is performed to remove excess tissue and create space in the back of the nose and mouth, relieving obstruction of the larynx.



**View of the soft palate being assessed for shortening (along the green line). Blue stars highlight the enlarged and prominent tonsils.**

If the laryngeal saccules are everted, they may be removed at the same time as the soft palate resection, or they may be left to return to a normal position if less severely affected.



**View of the larynx. Airflow is through the dark space (rima glottidis) between the vocal cords. Blue stars highlight the everted laryngeal saccules, which are capped with a plug of mucus.**

If the tonsils are enlarged and thought to be contributing to airway narrowing they may also be removed.